

## **Assessment of CT-KUB as A Diagnostic Tool for Renal Stone Assessment in the Pediatric Population**

Izhar Ali <sup>1</sup> and Muhammad Murtaza Azad <sup>2</sup>

<sup>1</sup> *Clinical fellow Philip G. Ransely Paeds Urology, SIUT Karachi, Pakistan*

<sup>2</sup> *Consultant Urologist, SHED Hospital Karachi, Pakistan*

**Abstract: Introduction** Pakistan possesses a larger stone burden in paediatric patients. In the paediatric population, proper and timely diagnosis of renal stones to get the best stone-free rates is essential. This study aims to assess CT-KUB as a diagnostic tool for renal stones in the paediatric population before PCNL. **Methodology** This is a retrospective, cross-sectional study. Patients between 1 – 15 years with a diagnosis of renal stones were included in the study. Radiological investigations including Ultrasound KUB, X-ray KUB, and before the procedure, CT-KUB were documented. Pre-operative, per-operative, and postoperative complications are used to assess the success of the procedure. The statistical package of Social Sciences 22 was used to enter, sort, and analyze the data. Variables were analyzed in mean  $\pm$  standard deviation and frequency and percentages. The chi-square test was used to assess the significance of mean differences keeping the p-value as  $\leq 0.05$ . **Results** The mean age was  $4.7 \pm 3.8$  years with a range of 1 -14 years. After the procedure, 104 (86.6%) were rendered stone-free after the first setting. Only 1 (0.8%) was converted to an open case (Pyelolithotomy). The mean stone size encountered was  $1.3 \pm 0.7$  cm in greatest dimension as measured on the CT scan. Postoperatively, there was a hemoglobin drop of  $2.3 \pm 0.5$  g/dl noted, mean operative time was  $94.8 \pm 17.4$  minutes. **Conclusion** CT KUB proves to be an important and accurate preoperative diagnostic tool in assessing patients with renal stones in the paediatric population.

**Keywords:** CT-KUB, mini-PCNL, Pediatric renal stone

Received: October 18, 2023

Accepted: December 28, 2023

DOI: 10.46568/bios.v5i1.180

**\*Correspondence:** Izhar Ali, Clinical fellow Philip G. Ransely Paeds Urology, SIUT Karachi, Pakistan. Tel: +92.333 9479785 Email: izharali1989.ia@gmail.com

### **Introduction**

Pakistan possesses a larger stone burden in paediatric patients. Total stone patients in Pakistan are 10- 15%. [1] Lying in the ‘stone belt’, the country poses multiple risk factors for stone formation, such as high ambient temperature, familial hyperoxaluria, and dehydration [2]. Certain regions in the country are ‘endemic’ for renal and bladder stones, especially in children. Malnutrition and dehydration are prime contributing factors to nephron-urolithiasis in children. Stones are mostly found in children with protein-calorie malnutrition (PCM), patients with congenital renal anomalies, and those with positive familial history. Many patients go undiagnosed till they present with a non-functioning kidney or worse, renal failure [3].

Renal stones are cleared by extracorporeal shockwave lithotripsy, percutaneous approach, endoscopic methods, or open surgical intervention. Depending on the stone size, site and consistency, and patient-related factors, the appropriate intervention is selected to achieve maximum stone clearance in the minimum possible settings [4]. These days, the advent of PCNL, Percutaneous Nephrolithotomy, has left behind open surgeries. The patient is rendered stone-free



**Biosight 2024; 05(01): 11-18**

via a keyhole incision, without the need for large incisions or transecting the pelvis. The patient undertakes the procedure in either a supine or prone position and the whole procedure is guided under fluoroscopy for better aim and stone clearance. The other minimally invasive procedure that is getting praise these days is called RIRS or Retrograde Intra Renal Surgery. It uses a flexible ureteroscope to reach every calyx of the pelvicalyceal system and clear the stone with a laser [5]. Both these procedures depend heavily on the pelvicalyceal anatomy. Anatomy is best delineated by a computed tomographic scan or CT scan. Plain CT KUB or CT Pyelogram is sufficient to outline the calyceal system. It also shows any presence of retrieval colon [6] or any other visceromegaly that may hinder or complicate the puncture, leading to hazardous complications. Thus, pre-operatively, it becomes easier to predict and comprehend the site and number of punctures and infra or supra-costal approaches. This helps in counselling the patient about anticipated complications and things to look out for [7]. Not only is CT scanning a good tool for the anatomical definition, but also the prime investigation to evaluate the exact consistency of stone. That is measured in terms of Hounsfield units with water being the baseline of Hounsfield Units of zero. The denser the stone, the higher the Hounsfield units, with Calcium Phosphate ranging up to 1600HU and being labelled 'as dense as a bone'. The softer stones (600-800 HU) can be cleared with extracorporeal shockwave lithotripsy while harder stones require intervention.<sup>8</sup>

Another advantage of CT is that the site and size can be rightly assessed, as compared to Ultrasound. The associated complications and anomalies can also be picked up with a keen eye on a plain CT KUB film, such as pelvic-ureteric junction obstruction (PUJO), duplication, ureteric course, adjacent organs, and any other obvious anomalies.<sup>9</sup> Also, the recent advancement in URO-DYNA CT being used operatively is also helping in the CT dominant PCNL workup.<sup>10</sup> This study aims to assess the beneficial effects of CT-KUB as a diagnostic tool for renal stones in the paediatric population before PCNL.

### **Methodology**

This is a prospective, cross-sectional study, conducted from October 2022 to March 2023 in the urology department of Godhra Muslim Hospital, Karachi, Pakistan. The sample size was calculated with the help of Rasoft sample size calculator keeping the total number of children, in 2022, aged between 1 – 15 years in Pakistan as the population, confidence interval as 90%, and the margin of error as 10%, the minimum required sample size was estimated as 199. Informed consent, in the language of understanding, was given to parents/guardians of patients before enrolment in study. Patients aged between 1 to 15 years, both genders, with flank pain, anuria, and previous diagnosis of renal stones were included in the study. After documentation of presenting complaints, history, and comorbidities/associated symptoms, Patients were requested to get radiological investigations including Ultrasound KUB, and X-ray KUB, and before the procedure, CT-KUB was done to investigate complete information, and results were documented. Pre-operative details including stone characteristics, degree of HDN, associated symptoms, and laboratory investigations were recorded. The patients with positive urine culture were treated accordingly, and per-operative details including operative name, the need for blood transfusion, converted to open, stone-free rates, haemoglobin drop, and DJ stent placement were documented. Post-operative complications including fever, haematuria, urine leakage, hospital stay, need for a re-do procedure, and residual stones were used to assess the success of the procedure. Follow-up was performed after 7 days of the procedure, and stone-free rates were confirmed on follow-up. Statistical Package of Social Sciences (SPSS) version 22 was used to enter, sort, and analyze the data. Variables such as age, operative time, haemoglobin drop, hospital stay, and stone size were analyzed in mean  $\pm$  standard deviation. Frequency and percentages were analyzed in frequency and percentages. Pre-operative results of Ultrasound, X-ray, and CT KUB were compared with

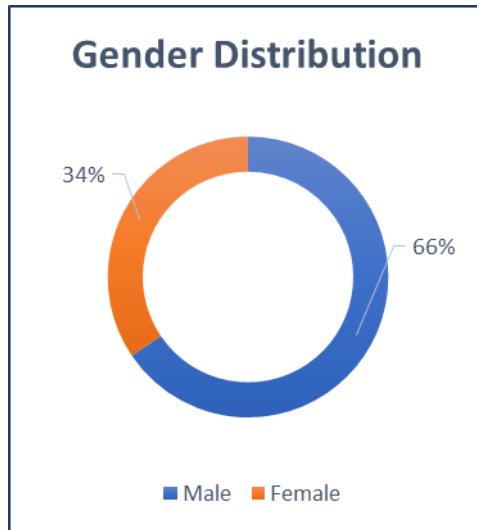


**Biosight 2024; 05(01): 11-18**

the help of the Mann-Whitney U-Test, The chi square test was used to assess the significance of mean differences keeping the p-value as  $\leq 0.05$ .

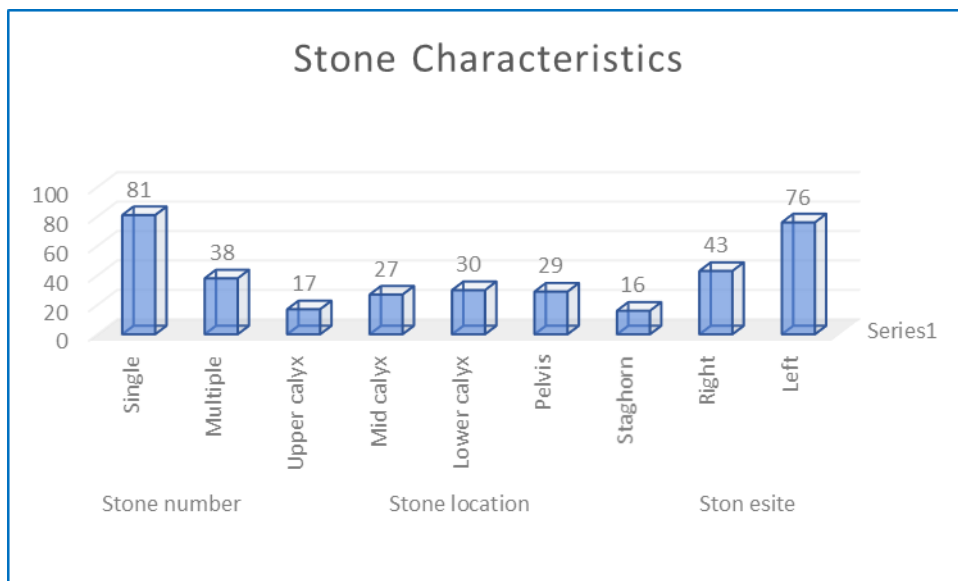
**Results**

A total of 119 children were enrolled in the study. The mean age was  $4.7 \pm 3.8$  years with a range of 1 -14 years. Gender distribution indicated male dominance with 78 (65.5%) frequency. **(Fig 1)**



**Fig 1:** Gender distribution frequency of study participants.

Stone characteristics are defined as stone numbers, stone site, and, stone location. Single stones were reported in 81 (68%) of participants while multiple stones were identified in 38 (31.9%). Stone site results indicated maximum stones from the left side kidney with 76 (63.8%), while stone location was evaluated and results reported maximum stones at lower calyx with 30 (25.2%), followed by lower calyx stone in 29 (24.3%), mid calyx stones with 27 (22.6%) and 16 (13.4%) staghorn stones. **(Fig 02)**



**Fig 2:** Stone characteristics of study participants.

A standardized procedure for percutaneous nephrolithotomy (PCNL) was used, and 14-16 Fr amplatz sheets were used for minimal invasion. Patients were kept in the prone position, after



**Biosight 2024; 05(01): 11-18**

general anaesthesia, pneumatic lithoclast and laser lithoclast were used to break the stones. The choice of lithoclast was made as per the requirement of stone characteristics. Intra-operative details were documented, recorded mean operative time was  $94.8 \pm 17.4$  mins, while only 01 patient (0.8%) was converted to an open pyelolithotomy and needed the blood transfusion intra-operatively. After achieving complete clearance on fluoroscopy, patients were transferred to the ward for follow-up.

After completion of the procedure, 104 (86.6%) were rendered stone-free on the first radiological investigation 12 hours before surgery. 11 patients (9.1%) had insignificant residual fragments on 12 hours of postoperative scans which reportedly subsided on radiological investigation after 72 hours of surgery. 04 (3.3%) had residual stones after 72 hours of radiological investigation, 3 (2.5%) were prescribed for medical expulsive therapy and 1 (0.8%) was advised for extracorporeal shockwave lithotripsy (ESWL). The mean stone size encountered was  $1.3 \pm 0.7$  cm in greatest dimension as measured on the CT scan. Postoperatively, there was a haemoglobin drop of  $2.3 \pm 0.5$  g/dl noted among patients. The mean hospital stay was documented as  $3.1 \pm 1.9$  days.

**Table 1****Table 1:** Outcome of PCNL, stone-free rates, and residual stone frequency.

Outcome	Number of Patients (%)
Stone-free	104 (86.6%)
Insignificant residual fragments	11 (9.1%)
Residual stones	4 (3.3%)
Converted to Open	1 (0.8%)

Post-operative complications including pain, fever, sepsis, and other associated symptoms were documented and results indicated that 11 (9.2%) patients developed a postoperative fever. 6 (5%) had to extend their hospital stay due to urinary leakage from the puncture site within 12 hours post-surgery. Only 1 (0.8%) patient required diversion in the form of Double J stenting for urinary leakage **Table 2**.

**Table 2:** Post-operative complications documented in study participants.

Post-operative complications	Number of Patients
Fever	11 (9.2%)
Extended Hospital Stay	6 (5%)
Urine leakage < 12 Hours	5 (4.2%)
Blood Transfusion	1 (0.8%)
DJ placement for Urine leakage	1 (0.8%)

**DISCUSSION**

As per the objective of this study, our results endorsed that CT-KUB is an excellent choice to diagnose renal stones in the paediatric population as the accuracy of results indicates a maximum understanding of stone size and location. Making it possible to achieve better stone-free rates. It is deemed as a very long debate about whether to expose children to radiation but as the exposure of CT scan is enough to obtain a complete scenario and pre-op requisites of PCNL, it is still considered the gold standard investigation before going for PCNL.<sup>13</sup> A study by Jaiswal P. et al studied on 414 retrospective CT scans and found that 313 of them had 'diagnostic' findings in terms of stones (92%), secondary causes of obstruction (7.9%), non-urolological findings (6%) and incidental findings (20.7%). They compared ultrasound with CT scan keeping CT scan as a gold standard.<sup>14</sup> The diagnostic yield of CT scan is furthermore elaborated in a study by Ganesan V et



**Biosight 2024; 05(01): 11-18**

al, published in 2016, where they compared the accuracy of Ultrasound with CT findings where CT was done within 60 days of ultrasound, and it was discovered that 1 in every 5 patients is being counselled wrongly based on ultrasound alone. The study recruited a total of 552 participants. About 22% (119/552) of the patients would be inadequately counselled. Stones that were classified as 5-10 mm based on the US had the highest probability (43% [41/96]) of having their management plan changed after a CT was done.<sup>15</sup>

Also, CT KUB provides a basic non-invasive, and accurate test of finding the composition of stone that can further decide the nature of the procedure to be performed. As mentioned previously, CT provides presumptive mention of stone composition, which further decides the management plan and decision to perform ESWL or to intervene or not. Similarly, the cut-off provided for RIRS is also accurately determined by CT scan and further leads to the decision of performing PCNL vs RIRS.<sup>16</sup> Furthermore, the use of low dose an ultra-low dose CT scan has emerged as the new alternative for exposing patients to the minimum amount of radiation whilst obtaining all the measures of stone consistency, size, site, and renal anatomy along with the general status of kidney, cortical thickness and grade of obstructive uropathy.<sup>17</sup> Also, low-dose CT is another great modality to confer in pregnancy and evaluate pregnant women with renal and/or ureteric stones, with a very low degree of damage to the fetus.<sup>18</sup>

However, another CT from the United States is in favour of ultrasound in detecting renal stones. This specific study by Roberson N et al published in 2018 studied 69 patients and reported ultrasound to have high specificity but moderate sensitivity with reported false negatives.<sup>19</sup> Relating to paediatric patients, CT provides an excellent diagnostic modality to provide all the above-mentioned parameters before proceeding with an intervention<sup>20,21</sup>. Especially, PCNL requires eliciting delineation of renal anatomy before proceeding. PCNL done with CT are more likely to be successful and stone-free as compared to those proceeded with ultrasound and x-ray KUB.<sup>22</sup> CT scans done before PCNL in paediatric patients also provide exclusive images of kidneys and bladder, ruling out any obvious morphological abnormalities and hence providing a clear image of the management plan. PCNL is considered a very safe procedure in the paediatric population, especially with the recent advances and miniaturization of instruments, and provides a very effective method of stone clearance in a single setting.<sup>23,24</sup> CT before the procedure results in achieving a better stone-free rate, fewer complications, and better prediction of complications or hindrances to be encountered.<sup>25</sup> CT also plays a dynamic role in the detection of residual stones after the intervention. The CT can also be done in low dose or ultra-low dose modality for follow-up scans that further reduce the radiation exposure and can image a very high-quality reconstructed image to show if any residual or new stone formation has occurred and also costs less than a conventional CT hence limiting the fear and concerns of the parents and patients.<sup>26</sup> The use of a uro-Dyna scan is also in mention that is an excellent modality for per-operative scan and evaluation of renal anatomy and stone location to further reduce the post-operative complications and overcome per-operative difficulties, it is a dynamic test and uses contrast to delineate and reconstruct three-dimensional images to better understand every calyceal variation.<sup>27</sup> All the above-highlighted points favour CT KUB in all aspects, and it is undoubtedly 'gold standard' for nephrolithiasis and preoperative assessment of a PCNL patient but it does pose a significant dent on the pocket. In countries where the patients are not insured for health and diagnostics, patients are reluctant and hesitate to undertake a CT scan because of the radiation exposure and because of the cost. A study by Bantavia et al, published in 2016, showed a drastic rise in paediatric nephrolithiasis but emphasizes the economic burden because of CT KUB and hence the circumstantial and unfortunate switching to ultrasound or combination of ultrasound and x-ray KUB for preoperative assessment for a paediatric PCNL patient<sup>28</sup>. This economic burden is better highlighted in developing countries where there are limited resources and access to radiological facilities is limited and sometimes, unapproachable also, the radiation exposure and risk of



**Biosight 2024; 05(01): 11-18**

carcinogenic potential causes the literate and more well-read subjects to refrain from obtaining a CT and opt for ultrasound and an X-ray combination.<sup>29</sup>

Another study rules out the favour of low-dose and ultra-low-dose CT scans. According to a systematic review, published in 2017 by Rob S. et al which reviewed 417 articles published over 20 years; low dose CT and ultra-low dose CT yielded comparable efficacious results in determining renal anatomy and stone site and composition. However, they were not effective in picking up stones of 3mm or lesser in size, also, they didn't show remarkable results in patients with a higher body mass index that is more than 30kg/m<sup>2</sup>.<sup>30</sup> Literature has proved that CT KUB is the best available radiological diagnostic tool for the assessment and accurate sizing of renal stones in the paediatric population, however, a study has evaluated the unnecessary radiation impact of CT KUB in paediatric patients, which can be avoided by using ultrasonography as radiological diagnostics tool, the results of the study identified that US KUB is beneficial for simple, single stone or multiple stones but not for smaller, tricky stones especially in patients with low BMI.<sup>31</sup>

**Conclusion**

CT KUB proves to be an important and accurate preoperative diagnostic tool in assessing patients with renal stones in the paediatric population. Our study showed a sample size of 119 and 86.6% indicated complete clearance per operatively.

CT KUB not only embarks on its importance in outlining the renal anatomy but also shows a hallmark description of stone parameters such as stone size, site, and density. Also, it clarifies the anatomy of adjacent structures and perceives what to anticipate in the procedure.

The introduction of low-dose and ultra-low-dose CT is also set to close the chapter on the risk of high ionizing radiation exposure. The cost of the CT remains the only negative factor against it, otherwise, the best modality before performing PCNL is CT KUB.

**ETHICS APPROVAL AND CONSENT TO PARTICIPATE**

Ethical approval was taken from healthcare institute; Informed consent in the language of understanding was signed by parents/guardian.

**HUMAN AND ANIMAL RIGHTS**

No animals were used in this study. The study on humans was conducted in accordance with the ethical rules of the Helsinki Declaration and Good Clinical Practice.

**CONSENT FOR PUBLICATION**

Not applicable.

**AVAILABILITY OF DATA AND MATERIALS**

None.

**FUNDING**

None.

**CONFLICT OF INTEREST**

The authors declare no conflict of interest, financial or otherwise.

**ACKNOWLEDGEMENTS**

None.



**REFERENCES**

1. Hussain M, Lal M, Ali B, Naqvi SAA, Rizvi SAH. Urolithiasis in Sindh: A single center experience with review of 10,000 cases. *J Nephrol Urol Transplant* 1998; 1: 10-3.2.
2. Ullah H, Aga S, Khatri S, Bajeer IA, Sultan S, Lanewala AA. Calculus anuria: A urological emergency with an excellent outcome. A retrospective review of pediatric population from a stone belt country, Pakistan.
3. Salah MA, Holman E, Khan AM, Toth C. Percutaneous cystolithotomy for pediatric endemic bladder stone: experience with 155 cases from 2 developing countries. *Journal of pediatric surgery*. 2005 Oct 1;40(10):1628-31.
4. Johri N, Cooper B, Robertson W, Choong S, Rickards D, Unwin R. An update and practical guide to renal stone management. *Nephron Clinical Practice*. 2010;116(3):c159-171.
5. Mahmud M, Zaidi Z. Percutaneous nephrolithotomy in children before school age: experience of a Pakistani center. *BJU international*. 2004 Dec;94(9):1352-4.
6. Chalasani V, Bissoon D, Bhuvanagir AK, Mizzi A, Dunn IB. Should PCNL patients have a CT in the prone position preoperatively?. *The Canadian journal of urology*. 2010 Apr 1;17(2):5082-6.
7. Ghani KR, Patel U, Anson K. Computed tomography for percutaneous renal access. *Journal of endourology*. 2009 Oct 1;23(10):1633-9.
8. Chua ME, Gomez OR, Sapno LD, Lim SL, Morales Jr ML. Use of computed tomography scout film and Hounsfield unit of computed tomography scan in predicting the radio-opacity of urinary calculi in plain kidney, ureter and bladder radiographs. *Urology annals*. 2014 Jul;6(3):218.
9. 4. Ali A, Akram F, Hussain S, Janan Z, Gillani SY. Non-contrast enhanced multi-slice CT-KUB in renal colic: spectrum of abnormalities detected on CT KUB and assessment of referral patterns. *Journal of Ayub Medical College Abbottabad*. 2019 Aug 2;31(3):415-7.
10. 24. Grüne B, Rassweiler-Seyfried MC, Müller K, Nuhn P, Michel MS, Younsi N, Stein R, Herrmann J. Ultra-mini-PCNL using the urological Dyna-CT in small infants: a single-center experience. *International Urology and Nephrology*. 2022 May;54(5):979-84.
11. Ibrahim B, Jeyakumar G, Ibrahim I, Hounat A. CT-KUB as gold standard for renal colic: A closed loop audit. *Clinical Radiology*. 2022 Nov 1;77:e22-3.
12. Jaiswal P, Shrestha S, Dwa Y, Maharjan D, Sherpa NT. CT KUB evaluation of suspected urolithiasis. *Journal of Patan Academy of Health Sciences*. 2022 Jun 17;9(1):58-64.
13. 9. Ganesan V, De S, Greene D, Torricelli FC, Monga M. Accuracy of ultrasonography for renal stone detection and size determination: is it good enough for management decisions?. *BJU international*. 2017 Mar;119(3):464-9.
14. 13. Harrington K, Torreggiani W. CT analysis of renal stone composition: A novel and non-invasive method to analyse stones. *Irish medical journal*. 2014 Mar 1;107(3):69-.
15. 15. KHALED IE, Doaa N, ALSHYMAA ZA, HOSSAM MA. Comparison between Low-Dose CT and Ultrasound in Diagnosis of Renal and Uretral Stones in Adults. *The Medical Journal of Cairo University*. 2019 Dec 1;87(December):4671-7.
16. White WM, Zite NB, Gash J, Waters WB, Thompson W, Klein FA. Low-dose computed tomography for the evaluation of flank pain in the pregnant population. *J Endourol*. 2007 Nov;21(11):1255-60. doi: 10.1089/end.2007.0017. PMID: 18042011.
17. 27. Roberson NP, Dillman JR, O'Hara SM, DeFoor WR, Reddy PP, Giordano RM, Trout AT. Comparison of ultrasound versus computed tomography for the detection of kidney stones in the pediatric population: a clinical effectiveness study. *Pediatric radiology*. 2018 Jul;48:962-72.
18. Ludvigson A, Motamedinia P. MP22-05 Does Ct Scan After Ultrasound Change Surgical Planning For Nephrolithiasis?. *The Journal of Urology*. 2021 Sep;206(Supplement 3):e392



**Biosight 2024; 05(01): 11-18**

19. Mustafa MM, Hassan IA, Elnour AM, Mohamed BH. Establishment of Computed Tomography National Diagnostic Reference Level (DRL) for Abdomen procedures in Paediatrics CT scan.
20. Oetama H, Mustafa A. Duodenal perforation and a broken guidewire fragment inside the duodenum during supine percutaneous nephrolithotomy (PCNL) without adequate prior imaging: a case report. *Urology Case Reports*. 2019 Jan;22:25.
21. Nerli RB, Ghagane SC, Mungarwadi A, Patil S. Percutaneous nephrolithotomy in children. *Pediatr Surg Int*. 2021 Aug;37(8):1109-1115. doi: 10.1007/s00383-021-04901-6. Epub 2021 Apr 15. PMID: 33856513.
22. Sabnis RB, Chhabra JS, Ganpule AP, Abrol S, Desai MR. Current role of PCNL in pediatric urolithiasis. *Current urology reports*. 2014 Jul;15:1-8.
23. Andrabi Y, Patino M, Das CJ, Eisner B, Sahani DV, Kambadakone A. Advances in CT imaging for urolithiasis. *Indian J Urol*. 2015 Jul-Sep;31(3):185-93. doi: 10.4103/0970-1591.156924. PMID: 26166961; PMCID: PMC4495492.
24. Fakhr Yasser A, Taheri D. Measuring Stone Free Rate after Mini Percutaneous Nephrolithotomy: Radiography, Ultrasound, or CT scan?. *Translational Research in Urology*. 2020 Apr 1;2(2):48-50.
25. Vicentini FC, Botelho LA, Braz JL, Almeida ED, Hisano M. Use of the Uro Dyna-CT in endourology—the new frontier. *International braz j urol*. 2017 Jul;43:762-5.
26. Van Batavia JP, Tasian GE. Clinical effectiveness in the diagnosis and acute management of pediatric nephrolithiasis. *International Journal of Surgery*. 2016 Dec 1;36:698-704.
27. Ashraf H, Saulat S, uddin Qadri SS, Amin D, Ayub A, Ejaz M. All That Glitter is not Gold: Computed Tomography-Kidney Ureter Bladder (CT-KUB) is not necessary for a Safe Percutaneous Nephrolithotomy. *Pakistan Journal of Medicine and Dentistry*. 2022 Sep 12;11(2):36-43.
28. Rob S, Bryant T, Wilson I, Somani BK. Ultra-low-dose, low-dose, and standard-dose CT of the kidney, ureters, and bladder: is there a difference? Results from a systematic review of the literature. *Clinical radiology*. 2017 Jan 1;72(1):11-5.
29. Kaul I, Moore S, Barry E, Pareek G. Renal Imaging in Stone Disease: Which Modality to Choose?. *Rhode Island Medical Journal*. 2023 Dec 1;106(11):31-5.
30. Edwan MA, Abdelaziz AA, El-Assmy AM, Abouelghar MI, Abdel-Baky HA. Impact of Pediatric Urolithiasis and its management on renal growth. *Journal of Pharmaceutical Negative Results*. 2023 Feb 6:713-26.
31. Ashraf H, Saulat S, uddin Qadri SS, Amin D, Ayub A, Ejaz M. All That Glitter is not Gold: Computed Tomography-Kidney Ureter Bladder (CT-KUB) is not necessary for a Safe Percutaneous Nephrolithotomy. *Pakistan Journal of Medicine and Dentistry*. 2022 Sep 12;11(2):36-43.

